

RADIO IDENTIFICATION METHODS FOR ARCHAEOLOGICAL HUMAN TEETH REMAINS: A SCOPING REVIEW

Metode Radio Identifikasi Untuk Temuan Arkeologi Gigi Manusia: Tinjauan Kelengkapan

Fahmi Oscandar¹, Dia Adinda Surya², Lutfi Yondri³

¹Department of Oral and Maxillofacial Radiology-Forensic Odontology, Faculty of Dentistry, Universitas Padjadjaran, Bandung, Indonesia

²Faculty of Dentistry, Universitas Padjadjaran, Bandung, Indonesia

³Research Center for Prehistoric and Historical Archaeology, BRIN, Indonesia
fahmi.oscandar@unpad.ac.id

Naskah diterima : 23 September 2022
Naskah direvisi : 20 Oktober 2022
Naskah disetujui : 6 Desember 2022

Abstract. *Identification of archaeological human teeth findings using a non-destructive method such as a radiograph is limited. Various methods have been used for archaeological human teeth findings, including 2D and 3D radiographs. This study examines the extent to which it is used, its advantages, and its limitations using the scoping review method. The search for articles referred to the Preferred Reporting Items for Systematic Review and Meta-analyses (PRISMA-ScR) was conducted through PubMed, Scopus, and ScienceDirect, published from 2012-2022. Articles were screened and assessed for eligibility. The initial search found 249 articles. After evaluating the eligibility criteria, 15 articles were selected. Studies addressing the criteria and other aspects were identified. Based on a study conducted on articles that met the criteria, it was concluded that the radio identification method has been utilized for various identification and that the most frequently used radio identification method is cone-beam computed tomography (CBCT).*

Keywords: *Radiograph, Human Teeth, Archaeology, 3D Radiograph, CBCT.*

Abstrak. Identifikasi temuan gigi manusia arkeologi menggunakan metode non-destruktif seperti radiografi masih terbatas. Berbagai metode telah digunakan untuk temuan gigi manusia arkeologi, termasuk radiografi 2D dan 3D. Penelitian ini mengkaji sejauh mana metode ini digunakan, kelebihan, dan keterbatasannya dengan menggunakan metode scoping review. Pencarian artikel mengacu pada Preferred Reporting Items for Systematic Review and Meta-analysis (PRISMA-ScR) yang dilakukan melalui PubMed, Scopus, dan ScienceDirect, yang diterbitkan pada tahun 2012-2022. Artikel-artikel disaring dan dinilai kelayakannya. Pencarian awal menemukan 249 artikel. Setelah mengevaluasi kriteria kelayakan, 15 artikel dipilih. Studi yang membahas kriteria dan aspek lainnya diidentifikasi. Berdasarkan studi yang dilakukan terhadap artikel yang memenuhi kriteria, disimpulkan bahwa metode identifikasi radio telah digunakan untuk berbagai identifikasi dan metode identifikasi radio yang paling sering digunakan adalah cone-beam computed tomography (CBCT).

Kata kunci: *Radiografi, Gigi Manusia, Arkeologi, Radiografi 3D, CBCT*

1. Introduction

The radiographic method is widely used in forensic odontology analysis activities because of its simple, economical, and non-invasive nature and does not directly come into contact with objects in the process of identification and analysis. Based on previous research, it was explained that the use of radiographs for dental identification purposes is considered accurate, reliable, and has many advantages, namely the identification process is simpler and takes less time than histological and biochemical methods (Putri, Nehemia and Soedarsono, 2013). So far, radiography is a good identification method because it is considered accurate and reliable. Besides that the radiographic method has many advantages, namely a simple identification process with a short time compared to other identification methods.

Forensic odontology is a field that includes, but is not limited to identification of human remains, identification of populations/ethnicities, sex determination, age estimation, and analysis of bite patterns, injuries, and disabilities (Pandey *et al.*, 2021). Methods Identification using teeth is considered very important because teeth have a high degree of individuality. In addition, teeth are hard tissues whose identification process is different from soft tissues. Soft tissues such as fingerprints and DNA are easily damaged, so visual assessment methods and examinations are often unusable. The use of radiographs can help overcome ambiguity in the dental identification process (Tanjung, 2021). Hence, because teeth have a high degree of individuality and are hard tissues that are not easily damaged, the identification method using teeth is considered very important, and to overcome ambiguity in the identification process, radiographic methods are used.

The techniques available today have broadened the investigation and exploration of human archaeological findings to study, characterize, and identify human archaeological findings. Teeth have become the focus of anthropologists and archaeologists because they can provide a lot of information about earlier humans, including cultural environment, location migration, pathology, morphological variations, age estimation, and sex differentiation (Garot *et*

al., 2017). Studying the archaeological findings of human skeletons helps us understand how humans in the past saw, felt, and responded to bodily processes such as appearance, health and disease, violence, aging, and death (Hosek and Robb, 2019). Additionally, radiograph has been used in analyzing human skeletal remains of archaeological findings to characterize or help diagnose unknown pathologies, estimate age at death, show traumatic injuries and provide indications of biological stress (Elliott, 2022).

Based on previous research, to avoid physically cutting teeth due to the limited archaeological samples of human teeth, several radiographic methods have been used, such as synchrotron microtomography, Cone Beam Computed Tomography, and Multi-Slice Computed Tomography to study the archaeological remains of humans. The handling of archaeological human remains requires great care and sensitivity due to their limited quantity and quality, so three-dimensional imaging with synchrotron microtomography has been proposed to avoid this damage. According to a study, researchers have successfully investigated the use of synchrotron radiation-based microtomography to estimate the age of death of 20 individuals from 20 teeth of archaeological collections from the 18th to 19th centuries (O'Hara *et al.*, 2019). In another study, CBCT has also previously been used in assessing human samples of archaeological findings for forensic purposes, mostly for the study of bones and teeth. CBCT has been of limited use so far in studying archaeological remains of humans. MSCT has also proven its ability in paleoimaging (Beschiu *et al.*, 2021).

So far, researchers from several countries have also used 2D radiograph methods, including portable X-ray devices, and 3D radiograph methods, such as micro-computed tomography (Micro-CT) and synchrotron microtomography to identify gender, estimate age, and identify pathological conditions in archaeological human teeth findings. A study conducted using the micro-CT found that high prevalence, characteristics and dens invaginatus (DI) were found in human tooth samples from the archaeological findings of Shaanxi, China, which lived 2,000 years ago). In

another study, researchers successfully presented the first detailed comparative study of human teeth recovered from Hexian archeological site using the micro-CT method (Xing *et al.*, 2014). Another study using a portable 2D X-ray device explained that age estimation based on the Demirjian method can be applied to third molars in human archaeological findings in Brazil (Maciel *et al.*, 2021). Research conducted using the synchrotron microtomography method explains that the cementum part of the teeth can be analyzed more easily, and Incremental layers are also easier to identify by using this method compared to other radiograph methods (Tanner *et al.*, 2021).

In Indonesia, the CBCT method has been used in archaeological research on human teeth, including a study conducted on the sagittal view of Pawon Humans and Modern Humans using Cone Beam Computed Tomography imaging (Senjaya, Oscandar and Yondri, 2012). The results of another study conducted with the Johanson method via 3D CBCT on prehistoric human findings in Pawon Cave, estimated the age of Pawon Man can be identified with more detailed and specific results compared to previous studies using the Brothwell method (Yondri, 2018). As far as the author's research results, it can be concluded that the radiographic method used in Indonesia to identify archaeological human teeth findings is CBCT.

As far as the authors know, no research has been found that reviews and compares the analysis of radiographic methods used in identifying human teeth in archaeological findings. This study uses a scoping review to help assess the scope, reach and characteristics so as to produce a mapping and broad overview of a topic in the literature to achieve the aims of the author's research. This study aims to examine the extent to which the use of, as well as the advantages and limitations of the radio identification method for human teeth found in archaeology using the scoping review method.

2. Method

Study Design

This scoping review seeks to examine the advantages and limitations of radio identification methods for archaeological human teeth findings. Scoping reviews are reported based on

the PRISMA Extension for Scoping Reviews (PRISMA-ScR) Checklist. The author follows the framework of Arksey and O'Malley, which outlines five key phases when conducting a scoping review: identifying research questions; identifying relevant studies; study selection; mapping data; and compiling, summarizing, and reporting the results. A literature search was conducted from October – December 2022 using the Pubmed, Scopus, and ScienceDirect databases using the keywords “(radiograph method) OR (radiograph identification) AND (archeological human teeth) OR (ancient human teeth remains)”.

Inclusion and Exclusion Criteria

The inclusion criteria in this study were articles that discussed the radiographic identification of archaeological human teeth findings, articles with research conducted on archaeological human teeth findings with radiographic methods, articles with the scope of international research, articles written in English, articles published within the last 10 years (2012-2022), and articles available in full text and free access. The exclusion criteria in this study were articles that had not been published internationally, review articles, and articles with fossilized human teeth as the research samples.

Article Selection

Manuscripts were retrieved by filtering the Pubmed, Scopus, and ScienceDirect databases. The first selection was carried out by filtering the publication year of the last 10 years. Further duplication filtering was carried out by downloading all search results from each database in RIS (Research Information Systems) format and exporting them to Mendeley software. Screening of titles and abstracts was then carried out to see the relevance of articles from the entire database. The remaining articles undergo a final screening by reading the entire contents of the article. Information regarding publication details, including author and publication date, as well as study details were obtained.

Mapping Process and Analysis

Data is managed in Microsoft Excel. The various uses, as well as the advantages and

limitations of radio identification methods of archaeological findings of human teeth, are included in this review as a supporting study. The author includes other aspects related to the method of radioidentification of human teeth, archaeological findings and other discoveries. The extracted data was then analysed using the thematic analysis method, which identifies common patterns or themes in the data. After analysing data from various sources, a structured discussion is formulated to address the research question.

Quality Assessment

The eligibility of articles resulted from the screening process using PRISMA-ScR (PRISMA extension for Scoping Reviews), which was developed according to the guidelines published by EQUATOR (Enhancing the Quality and Transparency of Health Research). Articles will be graded by three researchers to reduce bias.

3. Result and Discussion

3.1. Result

The database search reached 249 articles. The next selection was carried out by filtering the year of publication, namely the last ten years, as well as eliminating duplication with the Mendeley application, which resulted in 179 articles. Furthermore, the title and abstract screening stage resulted in 33 articles, and the full-text screening stage produced 28 potential articles relevant to this study. A flowchart is provided in Figure 1. A total of 15 articles were included and the articles were sorted chronologically according to the year of publication. The result is provided in Table 1.

3.2. Discussion

3.2.1. Utilization: Age Identification

In this study, it was found that the age of archaeological human findings can be identified by observing the teeth through radiographic scanning. Research unveils that teeth are one of the organs that can be used to estimate age, in addition to ossification of bones and diaphyseal length and development of the auricular ilium surface (Le Luyer *et al.*, 2016). This conforms to a study which elaborates that there is tooth morphology that can

be observed from radiographic scans to identify age approximately, one of which is by using the third molar mineralization approach. A total of 1198 dental radiographs were examined and assessed in one of four stages of periodontal ligament visibility. At that point, it was concluded that this method was successful in identifying the estimated age of human archaeological findings (Franklin, Swift and Flavel, 2016). However, these findings are inconsistent with a study that used pulp/tooth area calculations to investigate the human age of older archaeological findings. In this study it was explained that when estimating the age of death, measurements made directly on the teeth in some parts or half of the teeth were simpler to perform and provided more accurate data. Radiographic scans give inaccurate results, imaging sharpness and resolution lead to errors even after using computerized assistance; Incorrect positioning when taking radiographs causes rendering errors. There is a tendency to underestimate the actual age of individuals over 50 years of age, while the age of younger individuals is overestimated. Errors in underestimating age must be considered when using root dentine translucency and cementum annulation as individual criteria; however, the association between decreased pulp chamber size and increased age is only accurate for older individuals (D'Ortenzio *et al.*, 2018). In an alternate study, mentioned in Table 1, a study using 3D CBCT along with the Johanson technique to estimate the age of human archaeological findings was proven to give more specific results than the methods used previously (Yondri, 2018). Another finding elaborates how estimating the age of individuals from archaeological findings is as difficult as it is important. Identifying age estimation with teeth is considered more accurate than other methods, so in this study, the method of radiographic analysis of human third molar mineralization archaeological findings was used to identify the age estimation (Maciel *et al.*, 2021). However, these findings contradict research which explained that X-ray examination of the mummified samples failed to provide consistent data or detailed information about the mummy. However, the results of the CT scans performed by the researchers estimated that the mummified

sample under study died at the age of 35 based on analysis of the surface of the symphysis bones, which is about a decade older than the estimated results given by the X-rays, which is more consistent with its historical data (Saleem and Hawass, 2021). In addition, another study which conducted research on salt mummies found in Iran by CT scanning found that when relying solely on the aspect of dentition, only a rough estimate of the age of the mummies is possible (Öhrström *et al.*, 2021).

3.2.2. Utilization: Gender Identification

In addition to age estimation, sex identification is also important in archaeological research, which can be obtained by examining archaeological human teeth remains. The method of identifying sex using teeth is considered accurate, in line with the results of previous research conducted on 149 individuals from the Italian population of Samnites (III to V centuries Before Common Era (BCE)), which concludes that tooth dimensions were more prominent in males than females for the maxilla and mandible. The mandibular canines also had more significant sexual dimorphism, followed by the first and second molars. In this sample, sex determination was very accurate and complemented other methods used previously for 143 of 149 individuals with 95.97% success (Viciano, D'Anastasio and Capasso, 2015). Another study explained that there were consistent results with sexual dimorphism for internal crown structure, with males having higher enamel volume, dentin volume and DEJ area than females, which could be associated with higher dentin production in males compared to females (Le Luyer *et al.*, 2016). A different study presents that hard tissue of humans has been reported to yield approximately 100% accuracy in sex estimation in forensic anthropology, with the pelvis and skull being the most sexually dimorphic. Nonetheless, teeth are considered a better choice for forensic investigations because they are the hardest and most calcified structures that can withstand all kinds of decay, destruction, and degradation. Osteological and radiological examination methods are generally applied as they are fast, non-invasive and non-destructive

(Sehrawat and Singh, 2019). A more recent study, as mentioned in Table 1, found a general dimorphic pattern, namely the surface area and volume of dentin, roots, enamel, and crowns, which were larger in males than in females. Dimorphism in tooth tissue offers a new potential method for determining the sex of individuals, which is valuable in both forensic science and archaeology. However, population comparisons using volume and proportion of tooth tissue should only include individuals whose sex has been identified to avoid inaccurate results, and individuals whose ages are identified using current methods may be less accurate due to differences in enamel thickness in males and females (Fernée, Zakrzewski and Robson Brown, 2021). Opposite to these findings, a study which scanned salt mummies found in Iran with CT, including the areas of the jaws and teeth of 6 mummies found, explained that not all the sex of mummified samples could be identified. Further DNA analysis was necessary to confirm the sex of some samples (Öhrström *et al.*, 2021).

3.2.3. Utilization: Identification of Dental Pathological Conditions

In this study, it was found that radiographic scanning could identify pathological conditions of the teeth that were not visible on macroscopic examination. Research conducted on a 2000-year-old mummy with a CT scan explained that the radiograph method successfully demonstrated a form of dental treatment, namely a linen material filling the large interproximal cavities with a shield, possibly medicinal, which is an example of dental intervention in ancient Egypt (Wade *et al.*, 2012). However, a study, as presented in Table 1, explained that for mummies, macroscopic identification methods are only possible in a limited way. In the case of the Iceman, which was studied, intra-oral endoscopy was performed but could not reveal further diagnostics. Therefore, the investigation of the iceman mummy was based on the results of a CT scan (Seiler *et al.*, 2013). A contrasting study to this finding explained that if soft tissue is lost, dental pathologies, such as occlusal, more extensive approximal carious lesions or root caries and loss of alveolar bone, can be identified by visual inspection so that radiographic scanning is not

necessary (Seiler, Eppenberger and Rühli, 2018). As it was shown in Table 1, another study presents that micro-CT analysis of IGD in archeological human teeth findings is a valuable method that can assist in the process of identifying individuals who have vitamin D deficiency, especially in poorly preserved or incomplete human remains, and in those with has no observable macroscopic lesions. This method provides information about the age of onset and the number of deficiency periods, enabling a better understanding of the development of vitamin D deficiency during growth and development. (Veselka *et al.*, 2019). In another study with a scan performed using a 64-slice CT scanner, it was found that there was a dental filling material, most likely linen, to restore the strength and function of the teeth. However, these findings cannot be assumed as an example of dentistry. Better evidence is needed in future studies to prove invasive dentistry in ancient Egypt (Pantazis *et al.*, 2020). In line with this finding, a study explains that only well-preserved ancient Egyptian mummies in their original coffins can provide evidence of human involvement in tooth extraction, oral surgery, or other dental procedures. This study was carried out using the 3D CT scan method and obtained evidence of tooth extraction before death in the archaeological findings of humans studied, which the procedure can only be performed by a skilled person using the appropriate instrument (Olszewski *et al.*, 2021). In addition, another study compared macroscopic methods, CT radiographs, and large-volume micro-CT. This study successfully concluded that the volumetric capacity of LV micro-CT enables scanning of the entire skull, with teeth in-situ and yields sufficient information to investigate teeth pathologies in detail. The LV micro-CT scanning method can provide greater insight into the changes that occur in the teeth and the possible association of bone changes (developmental and pathological conditions), which may affect the teeth and alveolar bone. The large-volume micro-CT method can also provide data on an overall picture of health by examining the cranium and identifying diseases, such as pathological manifestations in the bones, that can affect tooth growth (Gurr *et al.*, 2022).

So far, radiographic methods have also been used to identify human dental anomalies in archaeological findings. As presented in Table 1, a study was conducted to identify dens invaginatus in human teeth found in archeology in China with the Micro-CT scanning method, which is now often used in scientific research due to its high resolution and non-invasive nature (Shi *et al.*, 2013). In another study, regarding dental fusion cases in archaeological human teeth findings in Greece, through radiographic scanning, found that the teeth studied showed two roots fused with two different root canals. Radiographic examination confirmed that the teeth were held together by dentine and validated by the pulp chamber, and each tooth retained its root canal (Tritsaroli, 2018). Furthermore, a study found that radiographic scanning methods can assist in the process of identifying human dental anomalies in archaeological findings. In this study, CBCT scanning was used, and no other supranumery dental anomalies other than mesiodens were found in the "individual 1" sample (Beschiu *et al.*, 2021).

3.2.4. Utilization: Identification of Tooth

Morphology

Morphology is an aspect that can be observed further with radiographic scanning, because several tooth morphology, such as roots, cannot be seen on macroscopic examination. A study, as presented in Table 1, explained that tooth morphology has been extensively studied by dental morphologists, anthropologists and palaeontologists to characterize and assess biological relationships within and between ancestors and modern humans to identify ethnic groups in forensic dentistry. CBCT was used in the present study, to evaluate the morphology of internal root canals in cases of archaeological human teeth remains. The high-quality scan results allow the root canal configuration to be analyzed for anthropological studies as the sample can be visualized internally with sufficient resolution to perform morphological analysis. The samples analyzed showed radicular anatomy and morphology similar to the current human population, and it was found that there is a high incidence of C-shaped molar roots

in the mandible (Ceperuelo *et al.*, 2014). This study aligns with a study that reveals variations in the number and shape of tooth roots that are genetically determined and can be traced to the ethnic origin of a population and the classification of hominids. This root canal configuration can be examined clinically via radiography, which is limited by its two-dimensional interpretation. More detailed three-dimensional information can be obtained from teeth extracted *in vitro* by tooth cleaning, staining, grinding, and separation, which would damage the specimen. In contrast, micro-CT and CBCT can provide accurate and detailed digital three-dimensional reconstructions of complex root canal anatomical configurations without damaging the sample. This CBCT study found a high prevalence of C-shaped root canals in the mandibular second molar sample (Ren *et al.*, 2020). In a different study, it is explained that the volumetric nature of the CT data set can minimize the potential for inaccurate calculations in dental cementum studies. As a non-destructive technique, the use of PPCI via synchrotron CT scanning enables the study of cementum in specimens previously unreachable by traditional destructive histological analysis of fossil and archaeological specimens. As there is no physical incision of the involved tissue for a CT scan, the resulting image is unaffected by tissue preparation artefacts such as scratches and tissue incisions resulting from the mechanical cutting process, which can obscure or alter image detail in cementum enhancement (Newham *et al.*, 2021).

3.2.5. Advantages and Disadvantages of Radio Identification of Archaeological Human Teeth Remains

As observed in this study, several methods of radioidentification of archeological human teeth remains were used, namely CT, MSCT, CBCT, and micro-CT, as tools to identify the estimation of age, sex, dental pathological conditions, and tooth morphology. Alongside the advantages of CT scans, specifically their non-invasive nature, a study unravels how CT scans have several drawbacks that must be considered for scanning archaeological human teeth findings, especially mummies. For example, few researchers have

considered how mummification might change the appearance of tissues. The quality of CT scan images is greatly reduced due to the attenuation of soft tissues compared to living humans and other changes that are less visible due to the embalming process of mummies (Cox, 2015). In an alternate study, it is explained that when fossil specimens are exposed to X-ray imaging, the matrix in which they are embedded can often distort the image, especially if the sediment has the same density or is denser than the surrounding skeletal tissue. Thus, plain film radiographs or 2D radiographs are only suitable for application to postcranial and dental skeletal specimens (Franklin, Swift and Flavel, 2016). A study, which was shown in Table 1, elaborates how measurement of the tooth cervix can be obtained using physical methods, or virtual by scanning a CT scan radiograph. A comparison of the two methods demonstrated the effectiveness and significance of virtual analysis in this field of study and allowed researchers to move from physical dental studies to virtual models (Kazzazi and Kranioti, 2018). In another investigation, it is described that conventional radiography and CT techniques do not provide sufficient detail for 3D analysis of bone microstructure and thus, micro-CT imaging is used (Shelmerdine *et al.*, 2018). Another study also compared portable digital planar X-ray equipment with conventional CT, where it was explained that portable digital planar X-ray equipment can be used directly at archaeological sites and has proven its toughness in extreme conditions. With some limitations, when investigations must be carried out under field conditions, conventional digital planar X-ray imaging remains an excellent and practical method that can obtain radiographic images of excellent diagnostic quality (Seiler, Eppenberger and Rühli, 2018). This study is in accordance with a follow-up study that demonstrated the feasibility of using field portable direct digital radiography equipment for mass radiographic examination of archaeological human findings. The portability offered by the equipment and its quick setup allows the entire study to be carried out in the field in less than three days with all radiographs carried out in 14 hours, with comparable examination times to other modern imaging modalities. The equipment's

portability and suitability for field conditions make this tool suitable for use in remote areas or developing countries where there's no access to fluoroscopy or MDCT. Therefore, this scanning method should be considered for inclusion in emergency response planning (Beckett *et al.*, 2020). A separate study explained that although the Micro-CT technique can provide higher resolution for the identification of complex canal anatomy, this technique is limited to in vitro applications and small areas, usually one tooth. The CBCT technique is routinely used for in vivo clinical applications and scans the larger viewing area of the maxilla and mandible for analysis of the remaining craniofacial skeleton. However, although CBCT scans provide clear images of internal root canal structures, intricate anatomical details are often missed, especially in calcified canals, which can lead to misidentification of the root type (Ren *et al.*, 2020). This finding is consistent with a research that compared the CBCT and MSCT methods for archaeological samples, which shed a light on its clinical applications, regarding diseases involving hard and soft tissues at the same time, which CBCT cannot replace conventional MSCT due to limited contrast resolution. However, CBCT has been successfully used for anthropological, forensic, and paleopathological studies, which mainly focus on mineralized human skeletal remains (Izzetti *et al.*, 2020). Opposite to these findings, a recent study compared medical CT, CBCT, and large volume micro-CT methods in their ability to scan archaeological findings of human samples. From this study it was found that an important difference between the micro-CT LV scanner and other CT systems is the scan slice thickness. CBCT and medical CT scanners produce scan slices measured in millimeters (mm), while LV micro-CT scanners have slice thicknesses in microns (μm). Differences in scan slice thickness are important when investigating small changes in structure, for example, details of tooth. In this research, it can be concluded that the LV micro-CT technique provides data that cannot be obtained using other macroscopic or radiographic methods and proves that LV micro-CT scanning is an advance over existing non-invasive methods (Gurr *et al.*, 2023).

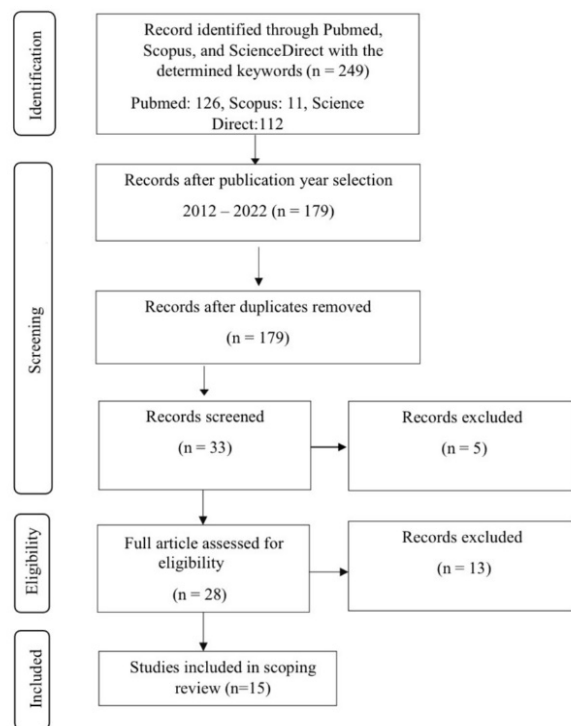


Figure 1. PRISMA-ScR flowchart

4. Conclusion

Based on a study conducted on articles that met the criteria, it was concluded that the radio identification method has been utilized for sex identification, age estimation, identification of pathological conditions, and identification of human tooth morphology in archaeological human teeth findings. It can also be concluded that the most frequently used radioidentification method is cone-beam computed tomography (CBCT), which is a technique that is non-invasive, accessible, accurate, and appropriate for scanning archaeological human teeth remains which are very limited in terms of quantity and quality.

Suggestion

This scoping review has some limitations, as relevant studies may have been excluded. Therefore, the author recommends further investigation into the application of radio identification methods to study archeological human teeth remains. This may be a potential avenue for further development in the field of forensic odontology, archaeology, and medical anthropology, with our study as a preliminary research foundation.

Acknowledgement

The authors acknowledge the guidance and support of Universitas Padjadjaran and its Directorate of Research and Community Service, which provided funding for this research article through the "Universitas Padjadjaran Lecturer Competency Research Scheme 2023" (Riset Kompetensi Dosen Universitas Padjadjaran 2023/RKDU). The authors also extend their gratitude to the staff of the Department of Oral and Maxillofacial Radiology-Forensic Odontology, Faculty of Dentistry, Universitas Padjadjaran, Bandung, Indonesia.

Author Statement

There are no conflicts of interest involved in this article, and no funding has influenced the content and substance of this article.

References

- Beckett, R.G. *et al.* (2020) 'Apaleoimaging study of human mummies held in the mother church of Gangi, Sicily: Implications for mass casualty methodology', *Forensic Imaging*, 23(November), p. 200416. Available at: <https://doi.org/10.1016/j.fri.2020.200416>.
- Beschiu, L.M. *et al.* (2021) 'An ancient mesiodens investigated by cone beam ct', *Applied Sciences (Switzerland)*, 11(24), pp. 1–18. Available at: <https://doi.org/10.3390/app112411703>.
- Ceperuelo, D. *et al.* (2014) 'Root canal morphology of chalcolithic and Early Bronze Age human populations of El Mirador Cave (Sierra de Atapuerca, Spain)', *Anatomical Record*, 297(12), pp. 2342–2348. Available at: <https://doi.org/10.1002/ar.22958>.
- Cox, S.L. (2015) 'A Critical Look at Mummy CT Scanning', *Anatomical Record*, 298(6), pp. 1099–1110. Available at: <https://doi.org/10.1002/ar.23149>.
- D'Ortenzio, L. *et al.* (2018) 'Age estimation in older adults: Use of pulp/tooth ratios calculated from tooth sections.', *American journal of physical anthropology*, 165(3), pp. 594–603. Available at: <https://doi.org/10.1002/ajpa.23371>.
- Elliott, J. (2022) 'Radiography of human dry bones: A reflective account with recommendations for practice', *Radiography*, 28(2), pp. 506–512. Available at: <https://doi.org/https://doi.org/10.1016/j.radi.2021.10.011>.
- Fernée, C., Zakrzewski, S. and Robson Brown, K. (2021) 'Dimorphism in dental tissues: Sex differences in archaeological individuals for multiple tooth types', *American Journal of Physical Anthropology*, 175(1), pp. 106–127. Available at: <https://doi.org/10.1002/ajpa.24174>.
- Franklin, D., Swift, L. and Flavel, A. (2016) "'Virtual anthropology" and radiographic imaging in the Forensic Medical Sciences', *Egyptian Journal of Forensic Sciences*, 6(2), pp. 31–43. Available at: <https://doi.org/10.1016/j.ejfs.2016.05.011>.
- Garot, E. *et al.* (2017) 'Analytical evidence of enamel hypomineralisation on permanent and primary molars amongst past populations /631/181/19/2471 /692/699 /123 article', *Scientific Reports*, 7(1), pp. 1–10. Available at: <https://doi.org/10.1038/s41598-017-01745-w>.
- Gurr, A. *et al.* (2022) 'Large Volume Micro-CT scanning of the dentoalveolar complex as a tool to evaluate dental health in an archaeological sample compared with traditional methods', *medRxiv*, Mic, p. 2022.06.23.22276834. Available at: <http://medrxiv.org/content/early/2022/06/28/2022.06.23.22276834.abstract>.
- Gurr, A. *et al.* (2023) 'Investigating the dentoalveolar complex in archaeological human skull specimens: Additional findings with large volume micro-CT compared to standard methods', *International Journal of Osteoarchaeology*, (November 2022), pp. 235–250. Available at: <https://doi.org/10.1002/oa.3204>.
- Hosek, L. and Robb, J. (2019) 'Osteobiography: A Platform for Bioarchaeological Research.', *Bioarchaeology International*, 3 1, pp. 1–15.
- Izzetti, R. *et al.* (2020) 'Cone-beam computed tomography vs. Multi-slice computed

- tomography in paleoimaging: Where we stand', *Homo*, 71(1), pp. 63–72. Available at: <https://doi.org/10.1127/homo/2020/1063>.
- Kazzazi, S.M. and Kranioti, E.F. (2018) 'Applicability of 3D-dental reconstruction in cervical odontometrics', *American Journal of Physical Anthropology*, 165(2), pp. 370–377. Available at: <https://doi.org/10.1002/ajpa.23353>.
- Le Luyer, M. *et al.* (2016) '3D models related to the publication: Internal tooth structure and burial practices: insights into the Neolithic necropolis of Gurgy (France, 5100-4000 cal. BC).', *MorphoMuseuM*, 2(1), p. e1. Available at: <https://doi.org/10.18563/m3.2.1.e1>.
- Maciel, D.R. *et al.* (2021) 'Estimation of age at death based on the analysis of third molar mineralization in individuals from Brazilian archaeological populations', *Bulletin of the International Association for Paleodontology*, 15(2), pp. 58–65.
- Newham, E. *et al.* (2021) 'A robust, semi-automated approach for counting cementum increments imaged with synchrotron X-ray computed tomography', *PLoS ONE*, 16(11 November 2021), pp. 1–26. Available at: <https://doi.org/10.1371/journal.pone.0249743>.
- O'Hara, M.C. *et al.* (2019) 'Safe Casting and Reliable Cusp Reconstruction Assisted by Micro-Computed Tomographic Scans of Fossil Teeth', *Anatomical Record*, 302(9), pp. 1516–1535. Available at: <https://doi.org/10.1002/ar.24047>.
- Öhrström, L.M. *et al.* (2021) 'Radiological and histological findings in ancient salt mummies from the salt mine of Douzklakh, Iran', *PLoS ONE*, 16(4 April), pp. 1–16. Available at: <https://doi.org/10.1371/journal.pone.0250745>.
- Olszewski, R. *et al.* (2021) *Medical and dental hidden treasures and secrets of 2700-year-old Egyptian mummy: Osirmose - the doorkeeper of the Temple of Re., Nemesis*. Available at: <https://doi.org/10.14428/nemesis.v17i1.61423>.
- Pandey, H. *et al.* (2021) 'Forensic Odontology: An Aid in Identification of Unknown Human Remains', *Medico-Legal Update*, 21(4), pp. 37–42. Available at: <https://doi.org/10.37506/mlu.v21i4.3099>.
- Pantazis, I. *et al.* (2020) 'A Ptolemaic mummy reveals evidence of invasive dentistry in ancient Egypt.', *Anatomical record (Hoboken, N.J. : 2007)*, 303(12), pp. 3129–3135. Available at: <https://doi.org/10.1002/ar.24487>.
- Putri, A.S., Nehemia, B. and Soedarsono, N. (2013) 'Prakiraan usia individu Melalui Pemeriksaan Gigi Untuk Kepentingan Forensik Kedokteran Gigi', *Jurnal PDGI*, 62(3), pp. 55–63.
- Ren, H.Y. *et al.* (2020) 'Mandibular molar C-shaped root canals in 5th millennium BC China', *Archives of Oral Biology*, 117(March), pp. 1–7. Available at: <https://doi.org/10.1016/j.archoralbio.2020.104773>.
- Saleem, S.N. and Hawass, Z. (2021) 'Digital Unwrapping of the Mummy of King Amenhotep I (1525–1504 BC) Using CT', *Frontiers in Medicine*, 8(December), pp. 1–15. Available at: <https://doi.org/10.3389/fmed.2021.778498>.
- Sehrawat, J. and Singh, M. (2019) 'Forensic odontological sex determination of Ajnala skeletal remains based on the statistical equations generated from the odontometrics of known teeth', *Forensic Science International: Reports*, 1(October), p. 100044. Available at: <https://doi.org/10.1016/j.fsir.2019.100044>.
- Seiler, R. *et al.* (2013) 'Oral pathologies of the Neolithic Iceman, c.3,300 bc', *European Journal of Oral Sciences*, 121(3 PART1), pp. 137–141. Available at: <https://doi.org/10.1111/eos.12037>.
- Seiler, R., Eppenberger, P. and Rühli, F. (2018) 'Application of portable digital radiography for dental investigations of ancient Egyptian mummies during archaeological excavations: Evaluation and discussion of the advantages and limitations of different approaches and projections', *Imaging Science in Dentistry*, 48(3), pp. 167–176. Available at: <https://doi.org/10.5624/>

- isd.2018.48.3.167.
- Senjaya, T., Oscandar, F. and Yondri, L. (2012) 'Difference of the size of average crown width first molar and second molar mandible of the Pawon Man with modern man', *Padjadjaran Journal of Dentistry*, 24(3), pp. 199–202. Available at: <https://doi.org/10.24198/pjd.vol24no3.26841>.
- Shelmerdine, S.C. *et al.* (2018) '3D printing from microfocus computed tomography (micro-CT) in human specimens: Education and future implications', *British Journal of Radiology*, 91(1088). Available at: <https://doi.org/10.1259/bjr.20180306>.
- Shi, S. *et al.* (2013) 'Dens Invaginatus in Ancient Chinese Teeth of 2,000 Years Ago', *Anatomical Record*, 296(10), pp. 1628–1633. Available at: <https://doi.org/10.1002/ar.22738>.
- Tanjung, R. (2021) 'Peran Radiografi Dalam Identifikasi Kasus Forensik Odontologi', *Jurnal Kedokteran Gigi Terpadu*, 3(2), pp. 16–20. Available at: <https://doi.org/10.25105/jkgt.v3i2.12615>.
- Tanner, C. *et al.* (2021) 'Extended-field synchrotron microtomography for non-destructive analysis of incremental lines in archaeological human teeth cementum', in *Proceedings of SPIE - The International Society for Optical Engineering*. Biomaterials Science Center, Department of Biomedical Engineering, University of Basel, Allschwil, 4123, Switzerland. Available at: <https://doi.org/10.1117/12.2595180>.
- Tritsaroli, P. (2018) 'A case of dental fusion in primary dentition from late bronze age Greece', *Balkan Journal of Dental Medicine*, 22(3), pp. 102–105. Available at: <https://doi.org/10.2478/bjdm-2018-0018>.
- Veselka, B. *et al.* (2019) 'Micro-CT assessment of dental mineralization defects indicative of vitamin D deficiency in two 17th–19th century Dutch communities', *American Journal of Physical Anthropology*, 169(1), pp. 122–131. Available at: <https://doi.org/10.1002/ajpa.23819>.
- Viciano, J., D'Anastasio, R. and Capasso, L. (2015) 'Odontometric sex estimation on three populations of the Iron Age from Abruzzo region (central-southern Italy)', *Archives of Oral Biology*, 60(1), pp. 100–115. Available at: <https://doi.org/10.1016/j.archoralbio.2014.09.003>.
- Wade, A.D. *et al.* (2012) 'Early dental intervention in the Redpath Ptolemaic Theban Male', *International Journal of Paleopathology*, 2(4), pp. 217–222. Available at: <https://doi.org/10.1016/j.ijpp.2012.09.005>.
- Xing, S. *et al.* (2014) 'Middle pleistocene hominin teeth from Longtan Cave, Hexian, China', *PLoS ONE*, 9(12), pp. 1–38. Available at: <https://doi.org/10.1371/journal.pone.0114265>.
- Yondri, L.- (2018) 'Age Estimation of Pawon Man Through Teeth Identification Using Johanson Method Through Cbct 3d Radiograph', *Amerta*, 36(1), p. 1. Available at: <https://doi.org/10.24832/amt.v36i1.188>.

Table 1 Study Results of Radioidentification Methods for Archaeological Human Teeth Findings.

No.	Authors (Year)	Title	Location	Sample	Location of Sample	Sample Periodization	Radiograph Method	Result	Conclusion
1.	Fernée, Zakrzewski, Brown (2021)	Dimorphism in Dental Tissues: Sex differences in Archaeological Individuals for Multiple Tooth Types	South hampton, UK.	1. Maxillary and mandibular incisors, canines and premolars with left and right sides. 2. The sample consisted of 300 teeth from 16 Females and 14 Males.	(i) Anglo-Saxon cemetery, Essex, UK (n=10) (ii) Early Medieval monastic cemetery, South Wales, UK (n=10) (iii) Late Medieval priority, Somerset, UK (n=10)	(i) 5 – 7th century. (ii) 7 – 11th century. (iii) 12 – 15th century	micro-CT	1. Significant differences in wear rates in the samples; in all cases, male crowns were found to have greater wear rates than female crowns. 2. Female enamel and crown sizes were found to be larger than those of males. 3. There was a significant difference in the teeth measurements, which is greater in males than females.	The common sexual dimorphic patterns identified were the greater surface area and volume of dentine, root, enamel and crown in males than in females.
2.	Maciel, et al. (2021)	Estimation of age at death based on the analysis of third molar mineralization in individuals from Brazilian archaeological populations	São Paulo, Brazil.	1. 21 third molars out of 11 individuals. 2. 18 developing teeth from 9 individuals (maxillary third molars, n = 4; mandibular third molars, n = 14).	(i) Piaçaguera, Brazil (n = 2) (ii) Buracão, Brazil (n = 2) (iii) Moraes, Brazil (n = 5)	(i) 7200-4200 before the present (BP) 1700-1400 BP (iii) 6800-5000 BP	Nomad direct current X-ray device.	1. This method presents good results with the age range of the catalogue used for the confrontation, with no statistically significant difference between them. 2. There is a positive correlation between estimates based on third molar development and those previously assigned based on tooth development and epiphyseal closure. 3. In one case (sample SB_7), the estimated age by third molar development analysis was slightly below the minimum age range.	Age estimation based on the Demirjian method applied to third molars showed good results in sub-adult individuals from Brazilian archaeological collections. To increase the accuracy of the estimates, Demirjian's method should be combined with other approaches commonly used in archaeology.

3.	Tanner, <i>et al.</i> (2021)	Basel, Switzerland.	4 archaeological human teeth findings from women with ages of death ranging from 30 to 60 years.	Collection of Basler Spitalfriedhof, Swiss.	19th century	<i>hard X-ray micro tomograms</i>	<p>1. The quality of the incremental line display can be improved by optimizing the angle of rotation.</p> <p>2. When the scale is 100 µm, this method cannot improve the display quality of incremental lines in all image regions.</p> <p>Acquisition time using this method is comparable to local tomography. The accuracy of age estimation using this method has not been evaluated. Overall, extended-field microtomography is a promising acquisition method for the non-destructive 3D characterization of incremental layers.</p>
4.	Beschiu, <i>et al.</i> (2021)	Basel, Switzerland.	Two out of six human remains found on the site:	Mosnita Veche "Dealul Salas", Romania.	<i>Eneolithic Period (Chalcolithic or Copper Age) 4500–2800 BC.</i>	CBCT	<p>1. No other superumerary teeth were found.</p> <p>2. The CBCT scan showed normal bone and root contours and no apical pathology in any of the teeth present.</p> <p>3. There is evidence of minor to moderate marginal bone loss, especially around the left upper premolar and left upper first molar, possibly due to periodontal disease.</p> <p>The "Individual 1" archaeological human jaw provides yet another piece of evidence of past human developmental anomalies. The presence of superumerary teeth in this sample is essential in establishing a database to compare the frequency and pattern of this pathology in ancient versus modern times.</p>

5. Olszewski, <i>et al.</i> (2021)	Medical and dental hidden treasures and secrets of 2700-year-old Egyptian mummy: Osirmose - the doorkeeper of the Temple of Re.	Brussels, Belgium.	Osirmose mummy, 2700 years old.	Temple of Re, Egypt.	Ancient Egypt Period, Dynasty XXV, 747-656 BC.	3DCT scanning	<ol style="list-style-type: none"> 1. The wear of the maxillary teeth is asymmetrical and more prominent in the maxillary. 2. Three anomalies were found in the maxilla. 	<p>The research team have managed to find the first evidence of a tooth extraction site and an oral surgical procedure performed on a 2700 year old mummy. Former tooth root extractions and opening of the tooth osteolytic lesion prior to the person's death.</p>
6. Pantazis, <i>et al.</i> (2020)	A Ptolemaic mummy reveals evidence of invasive dentistry in ancient Egypt.	Athens, Greece.	Mummy based on hieroglyphic inscriptions belonging to Sekhem, an adult male of Egyptian ethnicity, son of Ta-Khor.	Akhmin, Egypt.	The mid-Ptolemaic period to the early Roman Period (150-30 BC).	CT scanner 64-slice.	<ol style="list-style-type: none"> 1. The overall condition of the teeth is poor, showing signs of tooth wear, periodontitis, and disappearance of the periapicals. 2. The most significant finding in this study was the presence of a large interproximal carious cavity between the right mandibular second premolar and first molar, which was filled with hypodense material. 3. 3D reconstruction of the right side of the mandible showing the large cavity and material being inserted. 	<p>It can be assumed that the ancient Egyptians suffered from significant dental abnormalities. Despite their medical prowess and knowledge from ancient texts that the dental profession existed in ancient Egypt, there is insufficient evidence that invasive dentistry was performed. This finding can be described as a rare find, only the second such case in the literature, to the best of the authors' knowledge, that substantiates the theory of dental intervention in Ancient Egypt.</p>

7.	Ren, Zhao, Yoo, <i>et al.</i> (2020)	Mandibular molar C-shaped root canals in 5th millennium BC China	Shandong Province, PR China,	The craniofacial skeleton of 38 individuals (male (21), female (14), unknown sex (3), ages ranged from 15 to 40 years) consisting of 68 mandibular second molars.	Jiaoja, Shandong, Cina.	5000 SM	CBCT	<ol style="list-style-type: none"> 1. The percentage of C-shaped roots of the craniofacial bone in ancient samples on the left side is higher compared to modern clinical cases. 2. There is no correlation between age and the prevalence of C-shaped canals in ancient human skulls. 	<p>A high prevalence of C-shaped root canals in human mandibular second molars was found in archaeological findings at the Jiaoja site 5000 years ago. Their prevalence was higher than that of the control group with current clinical cases from the local population.</p>
8.	Veselka, <i>et al.</i> (2019)	Micro-CT assessment of dental mineralization defects indicative of vitamin D deficiency in two 17th–19th century Dutch communities	Leiden, Netherlands.	Two communities: (i) Beemster (MB11), with a skeletal sample of 59 non-adults and 200 adults (ii) Hattem (HT15), with a skeletal sample consisting of 21 adults and 88 adults.	(i) Province of North Holland (ii) Province of Gelderland, Netherlands.	(i) 19th century (ii) 17th-19th century	<i>micro-CT</i>	<ol style="list-style-type: none"> 1. Differences in the prevalence of IGD on micro-CT between Hattem women and men were not statistically significant, which may be partly attributed to the small sample size. 2. The majority of Hattem women present with no IGD visible on micro-CT, whereas the majority of males present with one or more IGD episodes. 3. It is not possible to assess the difference between the prevalence of IGD in male and female Beemster, as only two males had observable teeth. 	<p>This study suggests the histological analysis of the IGD, which will provide the most accurate results. However, this method provides information on the age of onset and the number of periods of deficiency, enabling a broader understanding of the development of vitamin D deficiency during growth and development. In addition, the non-destructive nature of this method makes it suitable for studying the valuable skeletal remains of ancient humans.</p>

9. Elizabeth, Yondri, Pramanik, Rusminah (2018)	Age Estimation of Pawon Man Through Teeth Identification Using Johanson Method Through CBCT 3D Radiograph	Bandung, Jawa Barat	Four out of five Pawon Man (i) Individual 1 (4 teeth attached to maxillary alveolar bone) (ii) Individual 3 (4 teeth attached to maxillary alveolar bone) (iii) Individual 4 (2 teeth attached to mandibular alveolar bone) (iv) Individual 5 (11 teeth attached to the maxillary and mandibular alveolar bone).	Pawon Cave, Cipatat, Bandung, Indonesia.	Late Pleistocene era, 3,000 – 11,000 years ago.	CBCT 3D	<p>1. The age estimation of Pawon Human method produces a more specific range compared to the method used previously, the Brothwell method.</p> <p>2. The estimated age produced by the Johanson method is 32-33.92 years for the first Pawon Man, 32,935-36,275 years for the third Pawon Man, 34.42 years for the fourth Pawon Man, and 27.36-31.35 years for the fifth Pawon Man.</p>	Johanson's age identification method with CBCT scanning is one of several nonclinical methods that can be used in the analysis of Pawon Human age estimation. Analysis using the Johanson method of the estimated age of the Pawon Man results in more specific and detailed results compared to previous studies using the Brothwell method.
10. Kazzazi, Kranioti (2018)	Applicability of 3D-dental reconstruction in cervical odontometrics	Edinburgh, UK.	530 maxillary and mandibular teeth from 51 skeletons (30 male, 21 female).	The Hasanlu and Dinkha Tepe collections are two sites in northwestern Iran.	Iron Age, 1200 BC.	CT Siemens Somatom 64-slice.	<p>1. Virtual cervical measurements do not differ significantly from actual measurements. Error analysis showed high replication of measurements with both measurement methods ($R > 0.99$).</p> <p>2.</p>	The results of this study indicate that virtual odontometric analysis is a reliable method, similar to traditional physical odontometric analysis. Currently, virtual systems are more suitable for fragile specimens, such as archaeological samples.

120	11. Seiler, Eppenberger, Rühli (2018)	Application of portable digital radiography for dental investigations of ancient Egyptian mummies during archaeological excavations: Evaluation and discussion of the advantages and limitations of different approaches and projections	Zurich, Switzerland	55 specimens, including 19 skeletal mandibles, 14 skeletal skulls, 18 separate mummified heads, and 4 partially preserved mummies.	Valley of the Kings, Luxor, Egypt.	The 18th dynasty of ancient Egypt (1550-1292 BC) and the 22nd Dynasty of Ancient Egypt (943-716 BC).	Digital portable digital X-ray planar.	<ol style="list-style-type: none"> 1. Only a portion of the teeth can be assessed with this projection. 2. The lateral-oblique projection can only be used for the mandible, Axial projection can be used on the skull and mandible. In addition, the maxillary and mandibular skeletons are accessible by a small, high-resolution dental detector. 3. This procedure is not applicable while the perioral soft tissue is still present. 	With some limitations, when investigations must be carried out under field conditions, conventional digital planar X-ray imaging remains an excellent and practical method for examining human archaeological findings, and radiographic images of excellent diagnostic quality can be obtained if a suitable methodology is used.
12.	Ceperuelo, <i>et al</i> (2014)	Root canal morphology of chalcolithic and Early Bronze Age human populations of El Mirador Cave (Sierra de Atapuerca, Spain)	Barcelona, Spain	Maxillary molars (13 first and 8 second molars) and 33 mandibular molars (17 first and 16 second molars) belonging to 17 individuals.	El Mirador Cavei Sierra de Atapuerca, Spain.	The Chalcolithic Period and the Bronze Age (Early Bronze Age)	CBCT	<ol style="list-style-type: none"> 1. 12.5% of molars from El Mirador Cave show evidence of C-shaped roots with separate canals. 2. This tooth feature is very common in mandibular second molars in today's Asian population. 	The samples show greater complexity in their canal system than other roots. Among the upper molars, upper M2 is the most variable tooth in terms of root and canal configuration.
13.	Shi, <i>et al</i> (2013)	Dens invaginatus in Ancient Chinese Teeth of 2,000 Years Ago	Xi'an, China	35 of the 67 samples were from 2,000 year old male subjects, with individuals aged between 15-45. There are 517 permanent teeth (224 anterior teeth and 293 posterior teeth).	Shaanxi, China.	The samples come from the Ancient Chinese civilization, 2000 years ago.	Inveon Micro-CT	<ol style="list-style-type: none"> 1. The overall prevalence of DI in the 67 humans from this archaeological finding was 31.34% (21 of 67). 2. DI was detected in 25 teeth with a prevalence of 4.83% (25 of 517). 	High levels of DI in the teeth of the Shaanxi individuals who lived 2,000 years ago were discovered using this method. It is not known whether the prevalence of DI is increasing or decreasing. These findings indicate that ancient Chinese teeth had a higher prevalence of DI than modern people.

14.	Seiler, <i>et al</i> (2013)	Oral pathologies of the Neolithic Iceman, c.3,300 bc	Zurich, Switzerland	Jaw of <i>Neolithic Iceman</i> .	Ortzi Alps Mountains at an altitude of 3210 m, Italy.	Neolithic Age, 3300 BC	<i>multislice computed tomography (MSC T)</i>	<ol style="list-style-type: none"> All teeth show a severe degree of abrasion, with a characteristic symmetrical pattern of wear on exposed dentin and subsequent enamel margins. Deep caries was found on the right upper first premolar and a small carious lesion on the mesial surface of the heavily abraded upper right first molar. There was severe periodontal bone loss, extensive periodontal, cusp fracture, and traumatic periodontal ligament widening. 	<p>CT scans from 2005 had limited resolution (slice thickness = 0.7 mm). This can result in jagged contours, which make analysis sometimes difficult. Despite the many conditions of dental pathology, the Neolithic Iceman may have had functional but sometimes painful teeth that provide us with a glimpse into co-evolutionary aspects of human lifestyle and ancient human dental disorders.</p>
15.	Senjaya, Oscandar, Yondri (2012)	Difference of the size of the average crown width first molar and second molar mandible of the Pawon Man with modern man	Bandung, Indonesia.	Pawon Man	Pawon Cave, Cipatat, Bandung, Indonesia.	Late Pleistocene era, 3,000 – 11,000 years ago.	<i>CBCT</i>	<ol style="list-style-type: none"> The average crown width of the mandibular first molars in Pawon Man is 11.74 with a standard deviation of 0.68, as for Modern Humans is 11.06 with a standard deviation of 0.32. The average crown width of second molars in Pawon Man is 11.61 with a standard deviation of 0.51, as for Modern Humans is 10.65 with a standard deviation of 0.49. 	<p>With the help of CBCT and digital measurements, it was concluded that there is a difference in the average crown width of mandibular first and second molars in Pawon Man and modern humans where the dental crowns of Pawon Man are larger than Modern Humans because Pawon Man eats hard and rough-textured food with simple food processing.</p>